

Two versus three implants for retaining mandibular overdenture with low profile attachment: a study of retention and peri-implant tissue health

Doaa A. Elmowafy,¹ Radwa M. K. Emera,² Salah A. Hegazy³

¹B.D.S., Faculty of Dentistry, Mansoura University, Egypt

²Associate Professor of Removable Prosthodontics, Faculty of Dentistry, Mansoura University, Egypt

³Professor of Removable Prosthodontics, Faculty of Dentistry, Mansoura University, Egypt

Correspondence: Radwa M. K. Emera, Associate Professor of Removable Prosthodontics, Faculty of Dentistry, Mansoura University, Egypt, Email drradwa@yahoo.com

Received: August 06, 2019 | **Published:** August 27, 2019

Copyright© 2019 Elmowafy et al. This is an open access article distributed under the terms of the Creative Commons Attribution License, which permits unrestricted use, distribution, and reproduction in any medium, provided the original author and source are credited.

Abstract

Purpose: To evaluate the effect of implants number for retaining mandibular overdenture with low profile (OT Equator) attachment regarding retention force and peri-implant tissue health.

Materials and Methods: In this self-controlled study, eighteen completely edentulous patients were selected. All patients received three implants in the mandibular midline and canine regions. Patient grouping was performed as follows, Group I: Where only the two terminal implants were used for retaining the overdenture with OT Equator attachment for all patients. Group II: Six months later, the middle implants were also loaded to share in overdenture retention with OT Equator attachment. Peri-implant soft tissue health and retention evaluation was carried out immediately after implants loading (T0), 3 months (T1), and 6 months (T2) later for both groups.

Results: There was statistically significant increase in retention in group II compared to group I at T1 (P=0.012), T2 (P=0.008), and T3 (P=0.006). Regarding peri-implant tissue health there was no significant difference in results between the two groups for all measured parameters.

Conclusion: Although both two-implants and three-implants retained mandibular overdenture with OT Equator attachments gave the same peri-implant clinical outcome, the three-implant retained mandibular overdenture provided higher retention forces. For both groups retention gradually decreased through the follow-up period due to wear occurring in OT Equator nylon inserts.

Keywords: implant retained overdenture, OT Equator, implants number

Abbreviations: MGI: modified gingival index, MPI: modified plaque index, PD: probing depth, CBCT: cone beam computed tomography

Introduction

For more than a century conventional complete denture had been the standard treatment option for edentulous patients. Although these patients are usually satisfied with the upper denture but majority of them often suffer from displacement of the mandibular denture.^{1,2}

Unlike the conventional complete denture, recent studies concluded that implant supported overdentures have excellent clinical results for maladaptive denture patients with promising long-term evidence supporting their effectiveness. Also, implant prosthesis has high patient satisfaction and increased success rates.^{3,4}

Variable attachment systems can be utilized in order to enhance overdenture retention and stability such as bar, ball, magnetic attachment, telescopic attachments and low profile attachments as locator and equator. Attachment type selection generally depends on the experience and preference of practitioners in addition to many other factors.⁵

In order to overcome restorative space insufficiency, the low profile attachment OT Equator has been developed which enables the

technician to utilize more space for an enhanced esthetic denture set-up and also for more prosthesis integrity.^{6,7}

There is limited evidence for the benefit of using two versus three-implants retained overdenture with OT Equator attachments for rehabilitation of the completely edentulous mandibular ridges. Therefore, the purpose of this study was to compare peri-implant tissue health and retention force of two versus three-implants with OT Equator attachments for retaining mandibular overdenture.

Material and Methods

Patients selection

Eighteen complete edentate patients were selected from the outpatient clinic of Prosthodontics Department with regard to the following selection criteria: all patients have adequate bone width and thickness for dental implant and bone density of type D3 at least verified by Cone Beam Computed Tomography (CBCT), one year at least after last extraction, covered with even thickness, firm healthy mucosa, normal maxillomandibular relation, adequate restorative space verified by putty index method. Patients with history of parafunctional habits, smoking, alcohol administration, systematic disorders affecting bone were excluded from this study.

Approval of this study protocol was done by the Faculty Ethical

Committee. All patients signed written consents after informing them about the detailed line of treatment and the needed follow-up visits.

Surgical procedures

For all the patients conventional complete dentures were fabricated. After one month of denture wearing to allow denture settlement. Mucosa supported stereolithographic surgical guide was fabricated aided by CBCT planning software (Figure 1A).

Under local anesthesia three implants (13mm length and 3.7mm diameter) (Dentium SuperLine, Dentium Co. Ltd., Korea) were inserted in the mandibular interforaminal region; one implant in the midline, and the two lateral implants at equal distance from the central implant in the canine region using the flapless surgical approach (Figure 1B). The mandibular denture was relieved over the implant sites and the implants were left submerged for three months according to the standardized two-stage protocol to allow for implant osseointegration.

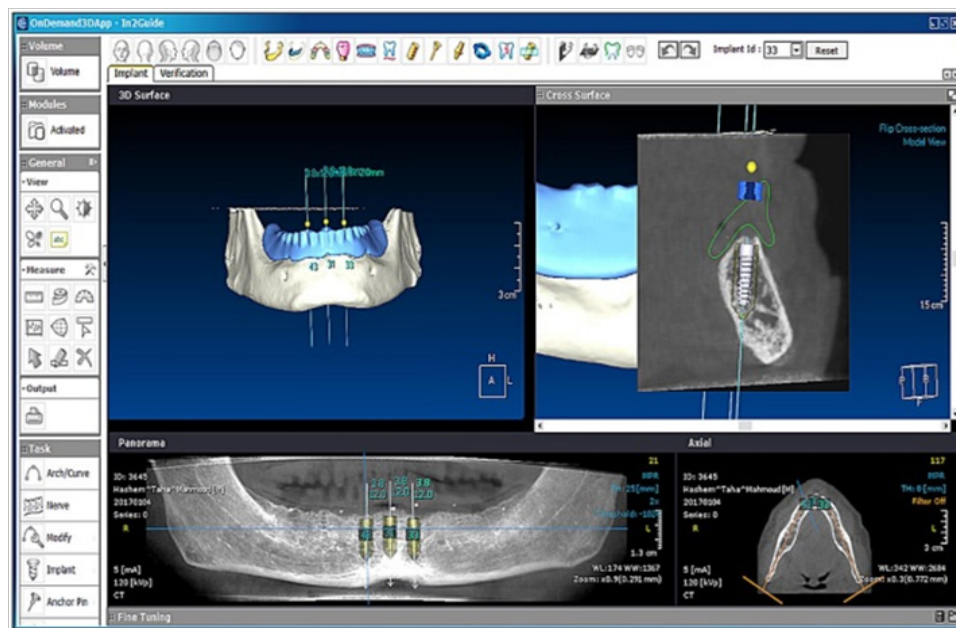


Figure 1A: Planning of ideal implant position and angulation.

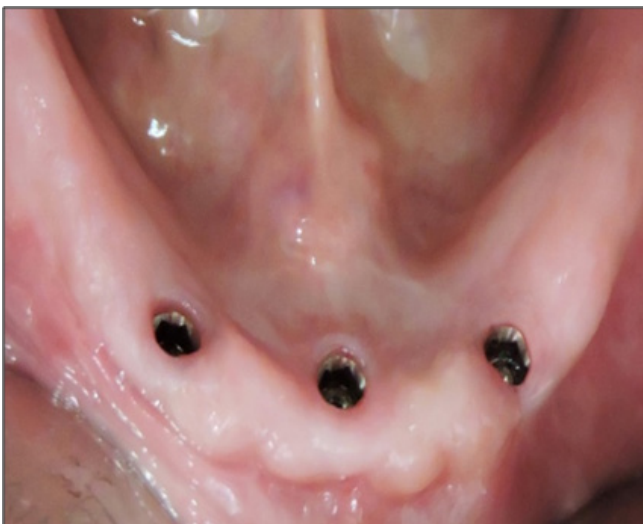

Figure 1B: Three implants were placed in the canine and midline region.

Patient grouping

Group I: Where only the two terminal implants were used for retaining the overdenture with OT Equator attachment for all the patients is as follows:

- * Small crestal incisions were made at canine regions bilaterally and the two lateral implants were exposed and cover screws were removed from the internal hex of implants and healing abutments were placed instead.
- * After two weeks, healing abutments were removed and the OT Equator abutments (Rhein83 Srl, Bologna, Italy) were attached to the implants intra-orally using the square screw driver for OT Equator attachment. Direct functional pick up of OT Equator metal cap to the denture fitting surface was accomplished by self-cure acrylic resin (Figure 2A). Pink nylon insert was placed into each Equator abutment using Equator insertion tool.
- * Measurement of retention force and evaluation of peri-implant tissue health was done for the two implants retained mandibular overdenture with Equator attachment at T0 (at time of overdenture insertion), T1 (three months) and T2 (six months) after overdenture use.

Group II: Six months later, the middle implants were also loaded to share in overdenture retention with OT Equator attachment through the following steps:

- * Within the same patient and after six months of denture loading, the midline implant was exposed and healing abutment was screwed to the internal hex of implant and left in place for 2 weeks.
- * OT Equator abutment was attached to midline implant instead of healing abutment. Pink nylon insert was placed into the

abutment using Equator insertion tool and direct functional pick up technique was done. (Figure 2B).

* Peri-implant soft tissue parameters including modified gingival

index, modified plaque index and probing depth were measured using calibrated plastic periodontal probe at T0, T1 and T2 (Figure 3A).

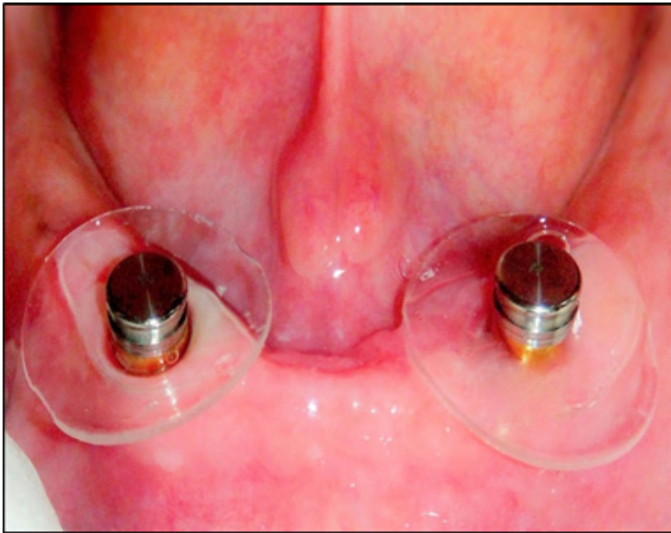


Figure 2A: Pick up of overdenture with two equators.

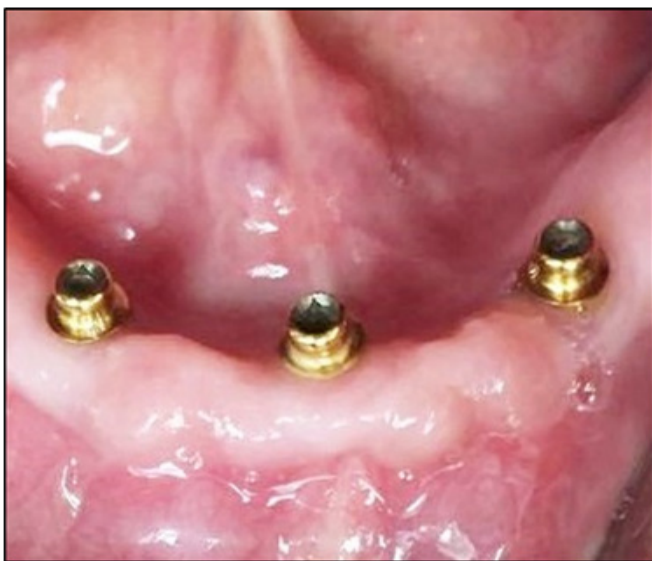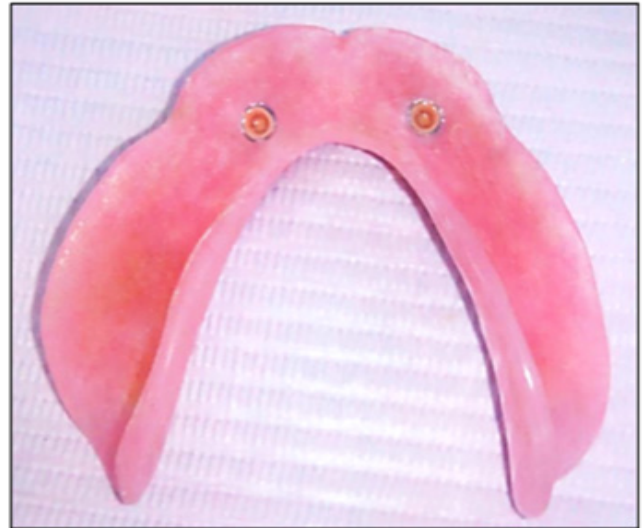

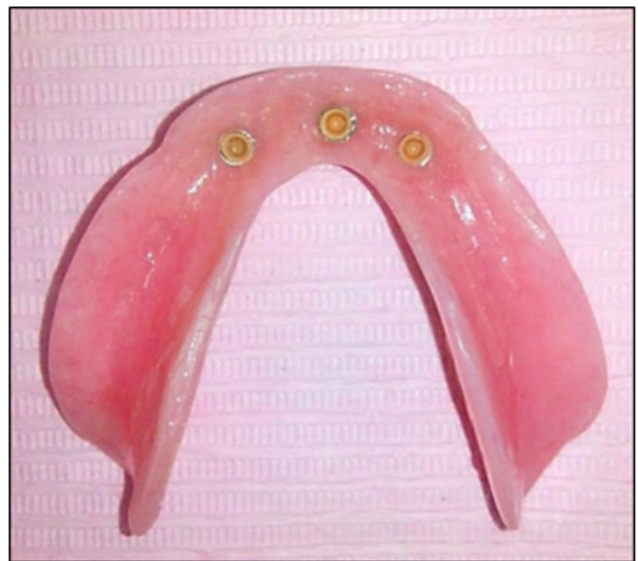
Figure 2B: Pick up of overdenture with three equators.



Modified Gingival Index (MGI)

Modified Gingival Index was scored 0 to 3 according to the following criteria:

- Score 0: Normal peri-implant mucosa (no redness, no swelling, and no bleeding).
- Score 1: Mild inflammation (slight change in color and slight oedema).
- Score 2: Moderate inflammation (redness, oedema, and glazing).
- Score 3: Severe inflammation (marked redness, oedema, and ulceration).

Modified Plaque Index (MPI)

Peri-implant plaque was assessed using a pressure sensitive plastic periodontal probe by Modified Plaque Index scores 0 to 3 as follows:

- Score 0: No plaque detected.
- Score 1: Plaque recognized only by running a probe across a smooth marginal surface of the implant abutment.
- Score 2: Plaque can be seen by naked eye.
- Score 3: Abundance of soft matter.

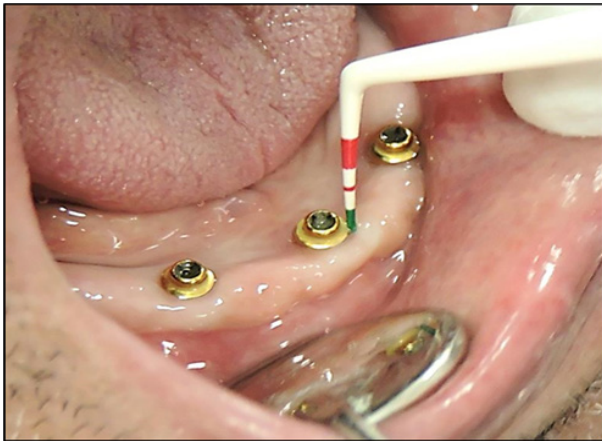


Figure 3A: Evaluation of peri-implant tissue health.

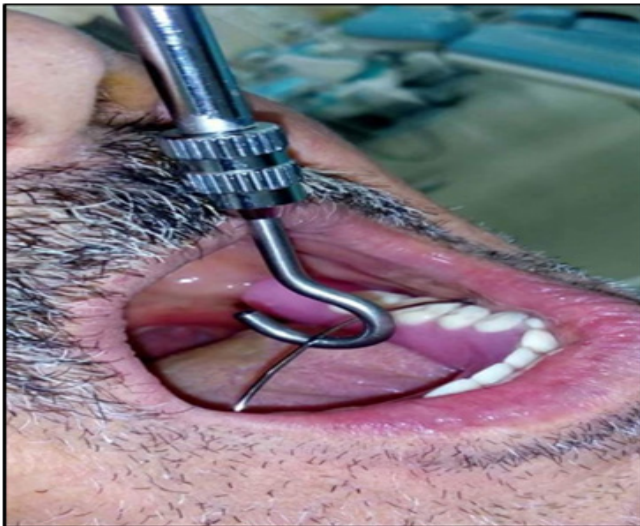

Figure 3B: Evaluation of retention using digital forcemeter.

Probing Depth (PD)

Probing Depth was measured by using a pressure sensitive plastic periodontal probe.

Retention measurement was done using digital Forcemeter and 0.9 diameter wrought wire that was attached to a metal hook fixed bilaterally to the overdenture polished surface between second premolars and first molars (Figure 3B).

Statistical Analysis

Statistical Analysis was made using SPSS software package version 20. Quantitative data were described using range (minimum and maximum), mean, standard deviation, and median. Significance of the obtained results was judged at the 5% level.



Results

Peri-implant soft tissue health

Table 1 shows the statistic analysis of modified gingival index, modified plaque index, and probing depth between T0, T1, and T2 for group I and group II.

- ▶ Results show insignificant increase in modified gingival index in group I and group II with advance of time at T0, T1, and T2.
- ▶ Results show insignificant increase in the modified plaque index in both group I and group II in T2 compared to T1.
- ▶ The mean peri-implant probing depth in the present study showed insignificant increase between group I and group II at (T0), (T1), (T2).

Retention

- ▶ Group II showed significant increase in retention in comparison to group I at significance level $p \leq 0.05$ as represented in Table 2.

- ▶ There was significant difference between group II and group I at T0 where $p=0.012$, T1 where $p=0.008$ and T2 where $p=0.006$.

Discussion

Peri-implant tissue health evaluation is very important for the detection of early signs of peri-implant diseases. Experimental and human studies have proved evidence that formation and development of a microbial biofilm is an important etiologic factor in the pathogenesis of peri-implantitis and subsequent marginal bone loss.¹¹

The results of the present study demonstrate minimal peri-implant soft tissue changes over the 6-month follow-up. No statistically significant difference was found for any of the studied clinical parameters (modified plaque index, modified gingival index and peri-implant probing depth) over the evaluation period. These findings are in agreement with other studies¹²⁻¹⁵ and may be attributed to the strict oral hygiene regime to which the patients were subjected provided healthy peri-implant tissues.

Additionally, this result may be due to tissue punch surgical technique followed in this study. This surgical technique resulted in

decreased bleeding, decreased tissue healing time and decreased peri-implant tissue changes following implant insertion. These advantages were in agreement with Kinsel and Liss¹⁶ who recommended tissue-punch protocol for the following advantages: maintenance or

enhancement of the soft tissue contours, reduction of alveolar bone resorption, avoid disruption of blood flow, reduced surgical trauma, and post-operative pain.

Table 1: Showing modified gingival index, modified plaque index, and probing depth at T0, T1, and T2 in group I and group II.

Modified Gingival Index				
Time	Group I (n = 6)	Group II (n = 6)	U	P
T0				
Min–Max	0.0–1.0	0.0–1.0		
Mean±SD	0.33±0.52	0.56±0.40	12.00	0.309
Median	0.0	0.50		
T1				
Min–Max	0.0–1.0	0.0–1.0		
Mean±SD	0.58±0.49	0.72±0.39	15.50	0.666
Median	0.75	0.84		
T2				
Min–Max	0.0–1.0	0.0–1.33		
Mean±SD	0.67±0.41	0.83±0.46	13.00	0.391
Median	0.75	1.0		
Modified Plaque Index				
T1				
Min–Max	0.0–1.0	0.67–1.0		
Mean±SD	0.67±0.52	0.89±0.17	16.00	0.702
Median	1.0	1.0		
T2				
Min–Max	1.0–2.0	0.67–1.0		
Mean±SD	1.17±0.41	0.95±0.13	12.50	0.176
Median	1.0	1.0		
Probing Depth				
T0				
Min–Max	0.50–1.0	0.50–1.04		
Mean±SD	0.70±0.17	0.74±0.18	0.397	0.700
Median	0.68	0.72		

Table Continued

Modified Gingival Index				
Time	Group I (n = 6)	Group II (n = 6)	U	P
T1				
Min–Max	0.50–1.13	0.59–1.08		
Mean±SD	0.77±0.22	0.80±0.16	0.226	0.826
Median	0.78	0.77		
T2				
Min–Max	0.50–1.19	0.67–1.21		
Mean±SD	0.81±0.23	0.88±0.18	0.577	0.576
Median	0.80	0.87		

Table 2: Comparison of retention force between the two studied groups.

Retention	Group I	Group II	T	P
T0 (at time of overdenture insertion)				
Min–Max	9.0–15.50	13.0–22.50		
Mean±SD	12.25±2.27	17.22±3.27	3.057*	0.012*
Median	12.0	16.65		
T1 (three months after insertion)				
Min–Max	8.20–14.60	12.80–22.0		
Mean±SD	11.63±2.24	16.92±3.18	3.327*	0.008*
Median	11.35	16.50		
T2 (six months after insertion)				
Min–Max	7.80–14.20	12.20–21.80		
Mean±SD	10.97±2.32	16.65±3.26	3.481*	0.006*
Median	10.50	16.20		

Statistical analysis of changes in mean values of modified gingival index showed insignificant difference between different follow-up periods. All evaluated patients showed stable and healthy peri-implant tissue in both groups. The level of inflammation was extremely low that only grade-I was detected in some cases. These healthy gingival conditions might be due to proper oral hygiene and also due to the small profile and smooth configuration of the Equator attachment.

Regarding the modified plaque index, it was slightly increased along the different time points in group I (over denture retained by

two equators); this may be due to the resiliency of the OT Equator attachment which allows denture movements and accumulation of food particles, and plaque under the denture. No statistical difference was identified. This can be attributed to strict plaque control measurements.

Group I showed more plaque accumulation in comparison to group II but the difference was insignificant. This may be due to increased rotational movement of overdenture retained by two equators only. The use of midline anterior implant would act as indirect retainer

that prevent overdenture rotation as detected by Ben-Ur et al.¹⁷ and confirmed by Emami et al.¹⁸

On the issue of periodontal probing depth, a progressive increase in probing depth may be an alarming sign for peri-implantitis occurrence. Therefore, the measurement of probing depth at the time of prosthesis insertion is critically important to allow comparison with future PD measurements.¹¹

A statistically insignificant difference was found between group I & II regarding peri-implant probing depth at different study period intervals. The results revealed that the probing depths were less than 1.5mm during the entire period of this study. These findings were in agreement with studies of Salvi et al.¹¹ and Neiva et al.¹⁹ that have concluded that successful implants allow probe penetration of approximately 3mm probing depths.

A minor non-significant increase in probing depth was noticed with advance of time in both groups that could be explained by increased peri-implant vertical bone loss and peri-implant gingival enlargement.^{20,21}

Regarding retention results, the retention values showed significant decrease due to wear of resilient overdenture attachments. According to Rutkunas et al.²² retention loss with equator attachment was mainly due to wear and permanent dimensional changes of the nylon inserts. This finding was in agreement with Abi Nader.²³

According to Passia et al.²⁴ and Ludwig et al.²⁵ resilient attachments exhibit wear under functional loading or after many cycles of insertion and removal which may be due to friction between male and female components. Similar findings were reported by Choi et al.²⁶

Satti et al.²⁷ also reported that the OT Equator system shows relatively more constant behavior of retention reduction and the OT Equator didn't show the trend of increasing retention in the first cycles that was noticed in the Locator samples. The change in OT Equator clear nylon inserts was minor and limited to the peripheral edges of the outer ring adjacent to the metal housing. These findings are compatible with the result of Alsabeeha et al.²⁸ and most in vitro studies.^{28,29}

The rate of retention loss in overdenture attachments was higher in attachment types which comprised plastic parts within their components rather than those totally made up according to Reda et al.³⁰

Evtimovska et al.³¹ explained that the reduction of the retentive capacity of the attachments attributed to the strain energy that absorbed during insertion and removal that may be divided into elastic (recoverable) and plastic (permanent) components. If permanent deformation occurs a rapid loss of retention will be observed.

Consequently, attachment wear causes loss of retention in dentures retained with attachment which is a major clinical problem that required periodic follow up of implant-assisted overdentures according to Chaffee and Felton.³²

Regarding the effect of increasing implant number on retention group II showed significant increase in retention in comparison to group-I and both groups showed retention values higher than 5N, the minimum retention required for stabilizing the prosthesis that could be considered suitable for clinical use.

These findings were in agreement with Uludag et al.³³ who

concluded that retentive values of the three-implant-assisted overdenture model are significantly higher than the two-implant overdenture model.

However, there is a controversy about the use of three-implants to assist mandibular overdenture over two-implants.

According to Oda et al.³⁴ three implants were more advantageous than the use of two-implants as it decreases denture base rotation during incising.

Additionally, Selda et al.³⁵ concluded that increasing of implant number tended to cause lower stresses in peri-implant bone in both splinted and un-splinted attachments that are induced by a bite force applied to the mandible.

Limitations of this study include insufficient number of patients and the need for prospective radiographic analysis.

Conclusion

Although both two-implants and three-implants retained mandibular overdenture with OT Equator attachments gave the same peri-implant clinical outcome. The three-implants retained mandibular overdenture provided higher retention forces. For both groups retention gradually decreased through the follow-up period due to wear occurring in OT Equator nylon inserts.

References

1. Cakarar S, Can T, Yaltirik M, et al. Complications associated with the ball, bar and locator attachments for implant-supported overdentures. *Med Oral Patol Oral Cir Bucal*. 2011;16(7):e953-959.
2. Feine JS, Carlsson GE, Awad MA, et al. The mcgill consensus statement on overdentures. Mandibular two-implant overdentures as first choice standard of care for edentulous patients. Montreal, Quebec, May 24-25, 2002. *Int J Oral Maxillofac Implants*. 2002;17(4):601-602.
3. Schmitt A, Zarb GA. The longitudinal clinical effectiveness of osseointegrated dental implants for single-tooth replacement. *Int J Prosthodont*. 1993;6(2):197-202.
4. Allen EP, Bayne SC, Brodine AH, et al. Annual review of selected dental literature: report of the Committee on Scientific Investigation of the American Academy of Restorative Dentistry. *J Prosthet Dent*. 2003;90(1):50-80.
5. Kim HY, Lee JY, Shin SW, et al. Attachment systems for mandibular implant overdentures: a systematic review. *J Adv Prosthodont*. 2012;4(4):197-203.
6. Zarb GA, Bolender CL, Eckert SE. Prosthodontic treatment for edentulous patient: complete dentures and implant supported prostheses. *Mosby*. 2004;191,206.
7. Urban D. Occlusion and Attachments the Underlying Scheme for Successful Overdentures. *Spectrum Dialogue*. 2010;9(4).
8. Trakas T, Michalakis K, Kang K, et al. Attachment systems for implant retained overdentures: a literature review. *Implant Dent*. 2006;15(1):24-34.
9. Alsabeeha N, Atieh M, Swain MV, et al. Attachment systems for mandibular single-implant overdentures: An in vitro retention force investigation on different designs. *Int J Prosthodont*. 2010;23(2):160-166.
10. Kirkpatrick L, Feeney B. A simple guide to IBM SPSS statistics for version 20.0. Student ed. *Wadsworth Cengage Learning*; c2013.

11. Salvi GE, Lang NP. Diagnostic Parameters for Monitoring Peri-Implant Conditions. *Int J Oral Maxillofac Implants*. 2004;19 Suppl:116–127.
12. Cordaro L, di Torresanto VM, Petricevic N, et al. Single unit attachments improve peri-implant soft tissue conditions in mandibular overdentures supported by four implants. *Clin Oral Implants Res*. 2013;24(5):536–542.
13. El-Sheikh AM, Shihabuddin OF, Ghoraba SM. Two versus three narrow-diameter implants with locator attachments supporting mandibular overdentures: a two-year prospective study. *Int J Dent*. 2012;2012:285684.
14. El-Sheikh AM., Shihabuddin OF, Ghoraba SM. A prospective study of early loaded single implant-retained mandibular overdentures: preliminary one-year results. *Int J Dent*, vol. 2012;2012:236409.
15. Ammar NA, El-Khodary NM, Abdelhamid AM. Clinical Evaluation of the Implant Retained Overdenture with OT-Equator Attachments. 2016;5(9):643–647.
16. Kinsel RP, Liss M. Retrospective analysis of 56 edentulous dental arches restored with 344 single-stage implants using an immediate loading fixed provisional protocol: statistical predictors of implant failure. *Int J Oral Maxillofac Implants*. 2007;22(5):823–830.
17. Ben-Ur Z, Gorfil C, Shifman A. Anterior implant-supported overdentures. *Quintessence Int*. 1996;27(9):603–606.
18. Emami E, de Souza RF, Bernier J, et al. Patient perceptions of the mandibular three-implant overdenture: A practice-based study. *Clin Oral Implants Res*. 2015;26(6):639–643.
19. Neiva RF, Neiva KG, Oh TJ, et al. Clinical and morphological aspects of the implant/soft tissue interface. *Int Chin J Dent*. 2002;2:151–61.
20. Elsyad MA, Al-Mahdy YF, Fouad MM. Marginal bone loss adjacent to conventional and immediate loaded two implants supporting a ball-retained mandibular overdenture: a 3-year randomized clinical trial. *Clin Oral Implant Res*. 2012;23(4):496–503.
21. Elsyad MA, Khairallah AS, Shawky AF. Changes in the edentulous maxilla with ball and telescopic attachments of implant-retained mandibular overdentures: a 4-year retrospective study. *Quintessence Int*. 2013;44(7):487–495.
22. Rutkunas V, Mizutani H, Takahashi H, et al. Wear simulation on overdenture stud attachments. *Dent Mater J*. 2011;30(6):845–853.
23. Abi Nader S, de Souza RF, Fortin D, et al. Effect of simulated masticatory loading on the retention of stud attachments for implant overdentures. *J Oral Rehabil*. 2011;38(3):157–164.
24. Passia N, Ghazal M, Kern M. Long-term retention behaviour of resin matrix attachment systems for overdentures. *J Mech Behav Biomed Mater*. 2016;57:88–94.
25. Wolf K, Ludwig K, Hartfil H, et al. Analysis of retention and wear of ball attachments. *Quintessence Int*. 2009;40(5):405–412.
26. Choi JW, Bae JH, Jeong CM, et al. Retention and wear behaviors of two implant overdenture stud-type attachments at different implant angulations. *J Prosthet Dent*. 2017;117(5):628–635.
27. Peck MT, Satti AA, Patel N. Comparison of Retentive properties of two Attachment Systems in Mandibular Overdentures - An in vitro study. *University of the Western Cape thesis*; 2013.
28. Alsabeeha NH, Payne AG, Swain MV. Attachment systems for mandibular two-implant overdentures: a review of in vitro investigations on retention and wear features. *Int J Prosthodont*. 2009;22(5):429–440.
29. Alsabeeha N, Atieh M, Swain MV, et al. Attachment systems for mandibular single-implant overdentures: an in vitro retention force investigation on different designs. *Int J Prosthodont*. 2010;23(2):160–166.
30. Reda KM, El-Torky IR, El-Gendy MN. In vitro retention force measurement for three different attachment systems for implant-retained overdenture. *J Indian Prosthodont Soc*. 2016;16(4):380–385.
31. Evtimovska E, Masri R, Driscoll CF, et al. The change in retentive values of locator attachments and hader clips over time. *J Prosthodont*. 2009;18(6):479–483.
32. Chaffee NR, Felton DA, Cooper LF, et al. Prosthetic complications in an implant-retained mandibular overdenture population: initial analysis of a prospective study. *J Prosthet Dent*. 2002;87(1):40–44.
33. Uludag B, Polat S. Retention characteristics of different attachment systems of mandibular overdentures retained by two or three implants. *Int J Oral Maxillofac Implants*. 2012;27(6):1509–1513.
34. Oda K, Kanazawa M, Takeshita S, et al. Influence of implant number on the movement of mandibular implant overdentures. *J Prosthet Dent*. 2017;117(3):380–385.
35. Selda A, Cengiz B, Hakan B, et al. The effect of attachment types and number of implants supporting mandibular overdentures on stress distribution: A computed tomography-based 3D finite element analysis. *J Biomech*. 2015;48(1):130–137.